

Recurrent condylar luxation after third molar extraction: an uncommon condition treated by eminectomy

*Luxação condilar recorrente após exodontia de terceiro molar: uma
condição incomum tratada através de eminectomia*

Maiolino Thomaz Fonseca OLIVEIRA^a, Átila Roberto RODRIGUES^a,
Flaviana Soares ROCHA^a, Darceny ZANETTA-BARBOSA^a

^aUFU – Universidade Federal de Uberlândia, Uberlândia, MG, Brasil

Resumo

Introdução: A exodontia dos terceiros molares raramente promove complicações pós-operatórias como desordens temporomandibulares. **Objetivo:** Embora a literatura apresente uma série de discussões sobre a evidência clínica relacionada a este assunto, neste artigo, apresentamos um caso incomum de uma paciente submetida à extração dos terceiros molares que apresentou, no acompanhamento pós-operatório, luxação condilar recorrente bilateral. **Conclusão:** Devido a este estado crítico, a paciente foi tratada com sucesso pela eminectomia bilateral após tentativas terapêuticas não cirúrgicas.

Descritores: Terceiro molar; articulação temporomandibular; cirurgia bucal.

Abstract

Introduction: Extraction of third molars can rarely provoke post-operative complications, such as temporomandibular joint disorders (TMDs). **Objective:** Although the literature presents a series of discussions of the clinical evidence related to this subject, in this report, we present an uncommon case of a patient submitted for the extraction of third molars who presented, in postoperative monitoring, with recurrent bilateral condylar luxation. **Conclusion:** Due to this critical condition, the patient was successfully treated by bilateral eminectomy.

Descriptors: Molar third; temporomandibular joint; surgery, oral.

INTRODUCTION

Third molar extraction remains one of the most frequent procedures performed by oral and maxillofacial surgeons, and complications can occasionally occur following these types of procedures¹. A careful taking of the medical history during the preoperative examination and good surgical planning are important to prevent such complications. However, infection after surgical procedures and other interurrences, such as nerve injuries, mandibular fractures, trismus, emphysema, bleeding events and temporomandibular disorders (TMDs), can occur during or after third molar extraction².

It seems feasible to hypothesize that third-molar extraction could increase the risk of TMDs. Often, the surgical procedure requires an extended mouth opening period that can cause joint pain and other symptoms. Additionally, the force applied to the jaw during the extraction of third molars can be associated with temporomandibular joint (TMJ) discomfort³; nevertheless, condylar luxation is an uncommon condition. Dislocation of the TMJ is the partial or complete loss of contact between the articular bone surfaces, in which the mandibular condyle

exceeds physiological movements and does not return to the correct position without the intervention of external forces. This condition is called recurrent when the patient has frequent episodes of luxation. Patients who already have recurrent condylar luxation are more vulnerable; as such, the extraction of third molars is more likely to increase the incidence of symptoms and the frequency of luxation in these patients. However, the development of recurrent luxation of the condyles after the extraction of third molars is a rare condition. In this report, we present an uncommon condition of recurrent condylar luxation after extraction of lower third molars, treated by bilateral eminectomy.

CASE REPORT

An 18-year-old female patient underwent surgery for extraction of the lower third molars under local anesthesia. The teeth were in position 2B and the procedure was similar on both sides. Osteotomy and dental section were performed during

surgery. Levers were used for extraction without the use of a bite block. According to the preoperative evaluation, the patient had no history of temporomandibular joint disorder or other systemic disorders. The patient complained of limited mouth opening and joint pain in the immediate postoperative period. However, on the ninth postoperative day, luxation of the mandibular condyles was observed, and manual reduction of the jaw was necessary. The patient received guidance on preventive care to avoid the recurrence of luxation, which was to maintain a light diet and to avoid excessive mouth opening; however, the episodes became increasingly frequent. On approximately the 22 day after third molar removal, the patient reported four daily episodes of luxation and had developed a method to reduce manually the jaw itself. In this situation, it was proposed as an immediate measure to mount orthodontic brackets for restricting mouth opening using elastics. For financial reasons, the patient opted for the installation of Erich bars (available in our service) and elastics use (Figure 1).

The patient was instructed to replace the elastics and was counseled regarding the possibility of undergoing bilateral eminectomy for the treatment of luxation. Even with the use of elastics, the patient had recurrent luxation. The patient opted for surgical treatment due to the clinical condition. Panoramic radiography was obtained to assist the preoperative planning. The eminectomy was performed under general anesthesia two months after the third molar extraction. The patient had an uneventful immediate post-operative period (Figures 2 and 3).

The condylar luxation episodes disappeared, and the patient did not have further complaints during the nine months of postoperative follow-up (Figure 4).

DISCUSSION

Postoperative complications can be associated with the extraction of third molars. Infection, nerve injuries, mandibular fractures, emphysema and temporomandibular disorders are complications that can require a new intervention^{1,2}. Extraction of third molars has been identified as a risk factor for temporomandibular joint disorders³⁻⁷. Prolonged mouth opening during extraction can cause pain, stretch the ligaments and displace the TMJ disc³; however, recurrent luxation of

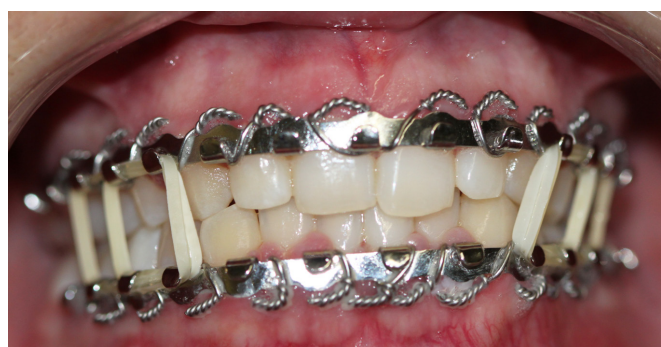

Figure 1. Restriction of mouth opening using Erich bars and elastic.

the mandibular condyles after extraction of third molars is uncommon.

We found no reports in the literature with similar situations to that described here. The relationship of third molar extraction with the development of temporomandibular disorders³⁻⁸ is known because the maneuvers used for extraction can cause discomfort to the TMJ. Additionally, the use of drills for dental section and osteotomy during third molar extraction requires maximal mouth opening. Levers are also employed for the removal of the teeth, and the applied force can be transferred to the temporomandibular joints. For some authors, there seems to be no link between the extraction of third molars and disc displacement without reduction⁹; however, recent research has shown that the extraction of third molars can be involved with the development of TMDs^{3,4}. What aroused our attention in this case was that the patient had no complaints before the extraction of the third molars; however, the postoperative period evolved into recurrent luxation of the mandibular condyle. Given the clinical evidence observed in our case, we associated the recurrent condylar luxation with extraction of the third molars.

There are many methods in the literature for the treatment of recurrent mandibular luxation. The conservative treatment includes restriction of mouth opening, a light diet, thermal physiotherapy, muscle relaxants and the use of sclerosing

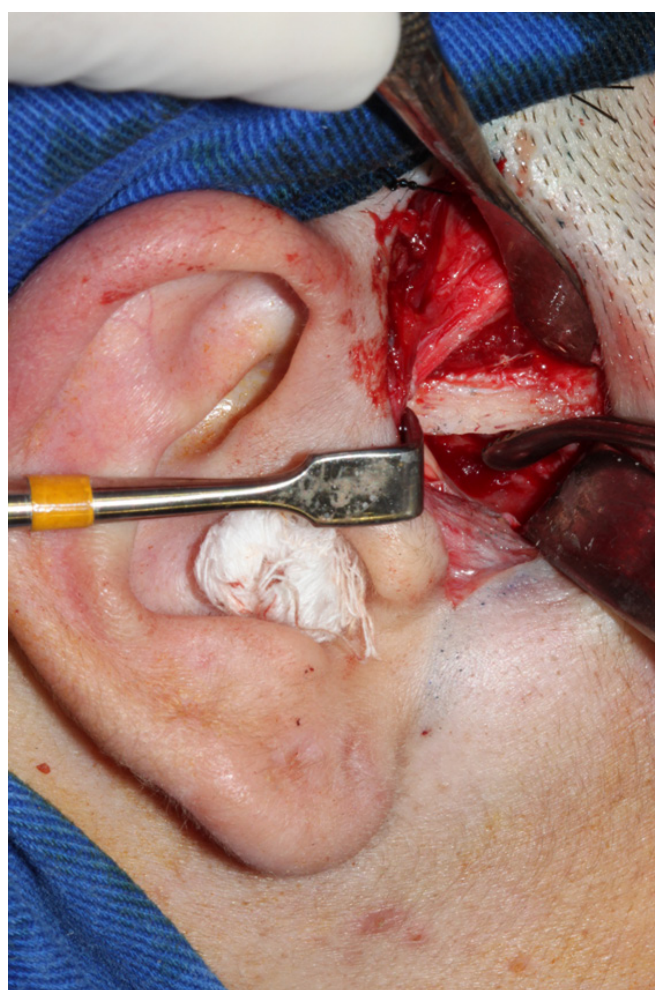


Figure 2. Resection of the articular eminence - right side.

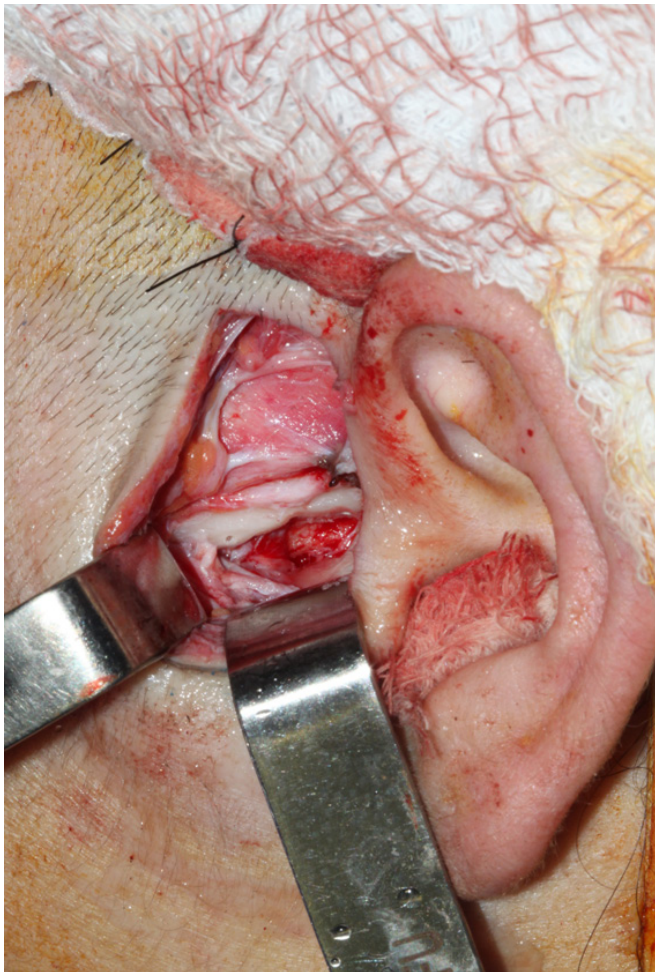


Figure 3. Resection of the articular eminence - left side.

substances, as well as the use of maxillo-mandibular and occlusal splints. Conservative management is frequently the first choice, as in the present report; however, it is often ineffective. Regarding surgical treatment, eminectomy, oblique osteotomy of the

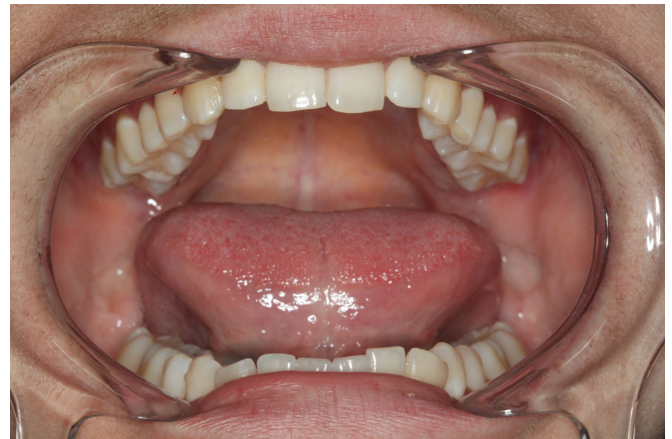

Figure 4. Maximum mouth opening showing proper joint function.

zygomatic bone, myotomy of the lateral pterygoid muscle and alloplastic grafts have been reported¹⁰.

Eminectomy involves the removal of the articular eminence by ostectomy, using rotary instruments. It is an effective treatment for recurrent condylar luxation with a simple surgical technique¹⁰, because with a preauricular approach, it is possible to remove to the articular eminence, providing better excursion of the condyles. Due to the high frequency of episodes of recurrent luxation in the present case, we chose to perform bilateral eminectomy as a treatment. Although evidence for the relationship between the extraction of third molars and the onset of temporomandibular disorders has been controversial, this case report supports this connection. Preventive care, including careful mandibular manipulation, force control and avoiding excessive mouth opening for a prolonged period, must be taken to prevent damage to the TMJ, especially during the extraction of lower third molars.

REFERENCES

1. Blondeau F, Daniel NG. Extraction of impacted mandibular third molars: postoperative complications and their risk factors. *J Can Dent Assoc.* 2007;73:325. PMID:17484797.
2. Bouloux GF, Steed MB, Perciaccante VJ. Complications of third molar surgery. *Oral Maxillofac Surg Clin North Am.* 2007;19:117-28. PMID:18088870. <http://dx.doi.org/10.1016/j.coms.2006.11.013>
3. DeAngelis AF, Chambers IG, Hall GM. Temporomandibular joint disorders in patients referred for third molar extraction. *Aust Dent J.* 2009;54:323-5. PMID:20415930. <http://dx.doi.org/10.1111/j.1834-7819.2009.01157.x>
4. Dodson TB, Susarla SM, Chuang SK, Donoff RB. Third molars and TMD. *J Am Dent Assoc.* 2007;138:576-8. PMID:17473030.
5. Huang GJ, Rue TC. Third-molar extraction as a risk factor for temporomandibular disorder. *J Am Dent Assoc.* 2006;137:1547-54. PMID:17082281.
6. Widmer CG. Third-molar extraction may increase relative risk for temporomandibular disorders. *J Evid Based Dent Pract.* 2008;8:40-2. PMID:18346706. <http://dx.doi.org/10.1016/j.jebdp.2007.12.012>
7. Huang GJ. Letter to the editor. *J Evid Based Dent Pract.* 2008;8:63. PMID:18492571. <http://dx.doi.org/10.1016/j.jebdp.2008.04.001>
8. Juhl GI, Jensen TS, Norholt SE, Svensson P. Incidence of symptoms and signs of TMD following third molar surgery: a controlled, prospective study. *J Oral Rehabil.* 2009;36:199-209. PMID:19207447. <http://dx.doi.org/10.1111/j.1365-2842.2008.01925.x>
9. Threlfall AG, Kanaa MD, Davies SJ, Tickle M. Possible link between extraction of wisdom teeth and temporomandibular disc displacement with reduction: matched case control study. *Br J Oral Maxillofac Surg.* 2005;43:13-6. PMID:15620768. <http://dx.doi.org/10.1016/j.bjoms.2004.10.001>

10. Vasconcelos BC, Porto GG. Treatment of chronic mandibular dislocations: a comparison between eminectomy and miniplates. *J Oral Maxillofac Surg.* 2009;67: 2599-604. PMID:19925978. <http://dx.doi.org/10.1016/j.joms.2009.04.113>

CONFLICTS OF INTERESTS

The authors declare no conflicts of interest.

CORRESPONDING AUTHOR

Maiolino Thomaz Fonseca Oliveira

Área de Cirurgia e Traumatologia Buco-Maxilo-Facial e Implantodontia, UFU – Universidade Federal de Uberlândia,

Av. Pará, 1720, Bl. 4T, 38405-900 Uberlândia - MG, Brazil

e-mail: maiolinothomaz@gmail.com

Received: December 19, 2012

Accepted: May 13, 2013